

## **VII. Chest pain**

Erica Friedman, MD

Associate Dean of Undergraduate Medical Education

Mt. Sinai School of Medicine

### **Specific Learning Objectives**

#### **1. Knowledge:**

Subinterns should be able to describe and define:

- a) The historical, physical examination, electrocardiographic, laboratory and radiographic findings of serious cardiopulmonary etiologies of chest pain, including:

Serious and potentially life threatening causes:

- (1) Acute coronary syndromes (ST Elevation MI and non-ST Elevation MI)
- (2) Pulmonary embolism
- (3) Pneumothorax
- (4) Aortic dissection
- (5) Pericarditis
- (6) Pneumonia

Non-life threatening causes of acute chest pain including:

- (1) Esophageal reflux and spasm
- (2) Peptic ulcer disease
- (3) Musculoskeletal strain
- (4) Rib fracture
- (5) Costochondritis
- (6) Biliary colic
- (7) Pleurisy
- (8) Intercostal neuritis

- b) The role of laboratory testing in the diagnosis of chest pain
- c) The role of radiological studies in the diagnosis of chest pain
- d) Appropriate clinical situations in which a patient should be transferred to telemetry monitored unit or intensive care unit or require an immediate consult or intervention (PCI, thrombolytic therapy, etc)
- e) Situations in which it is necessary to seek support from supervising resident and/or faculty emergently
- f) Sensitivity and Specificity of findings and lab data in ruling in or out a diagnosis

#### **2. Skills:**

Subinterns should be able to:

- a) Conduct an appropriately focused history and physical exam
- b) Perform an appropriately focused chart review
- c) Acquire and interpret an electrocardiogram
- d) Create a differential diagnosis
- e) Develop a management plan
- f) Provide appropriate treatment and/or analgesia for patients without an acute coronary

syndrome

- g) Obtain timely input from supervising resident and/or faculty
- h) Plan the transfer of a patient to a telemetry-monitored unit or intensive care unit when appropriate
- i) Appropriately activate the emergency cardiac/respiratory arrest team when needed

### 3. Attitudes and professional behavior:

Subinterns should demonstrate:

Compassion towards patient's wishes with regards to resuscitation and mechanical support

### Case I: Chest Pain

SCENARIO: You are on call for the general medicine team and are cross-covering for a colleague. A nurse from the stepdown unit (telemetry) calls you about Mr. Frasier, a patient of Dr. Nash's, who is complaining of chest pain.

1) Question: what additional immediate information would you like to obtain from the nurse over the phone?

Mr. Frasier's heart rate is 62 and regular, his BP is 110/75, RR of 16, and O2 sat of 94% on room air. His chest pain is in the substernal region radiating to the back, started about 5 minutes ago while he was resting in bed and is a 6/10 in severity. He has some mild dyspnea but no diaphoresis, nausea, or palpitations. He is a 69-year-old man admitted for unstable angina to the CCU last night. He has ruled out for MI by serial cardiac markers and EKG's, has had no chest pain since admission, and after cardiac cath one hour ago was sent to the stepdown unit. He has a history of hypertension and diabetes but had no previous history of cardiac disease. His cath showed extensive triple vessel disease and he is awaiting bypass surgery. His current meds include atenolol, lisinopril, isosorbide dinitrate, ASA, insulin, IV NTG, and IV heparin.

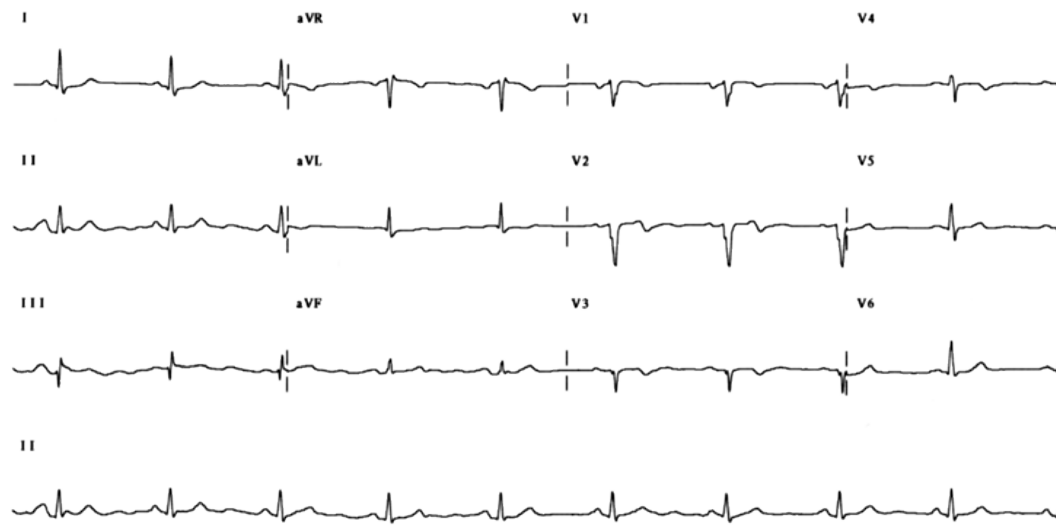
2) Question: are there any telephone orders you would like to give the nurse?

3) Question: What are your thoughts about a differential diagnosis as you proceed to the patient's room?

4) Question: What additional chart information do you want?

The patient's CBC this morning pre-cath was 12.5/38 (Hgb/Hct); his renal and liver functions are normal, and he has no drug allergies. He is a full code status.

Baseline EKG:



5) Question: What factors will influence your decision to call your resident right away?

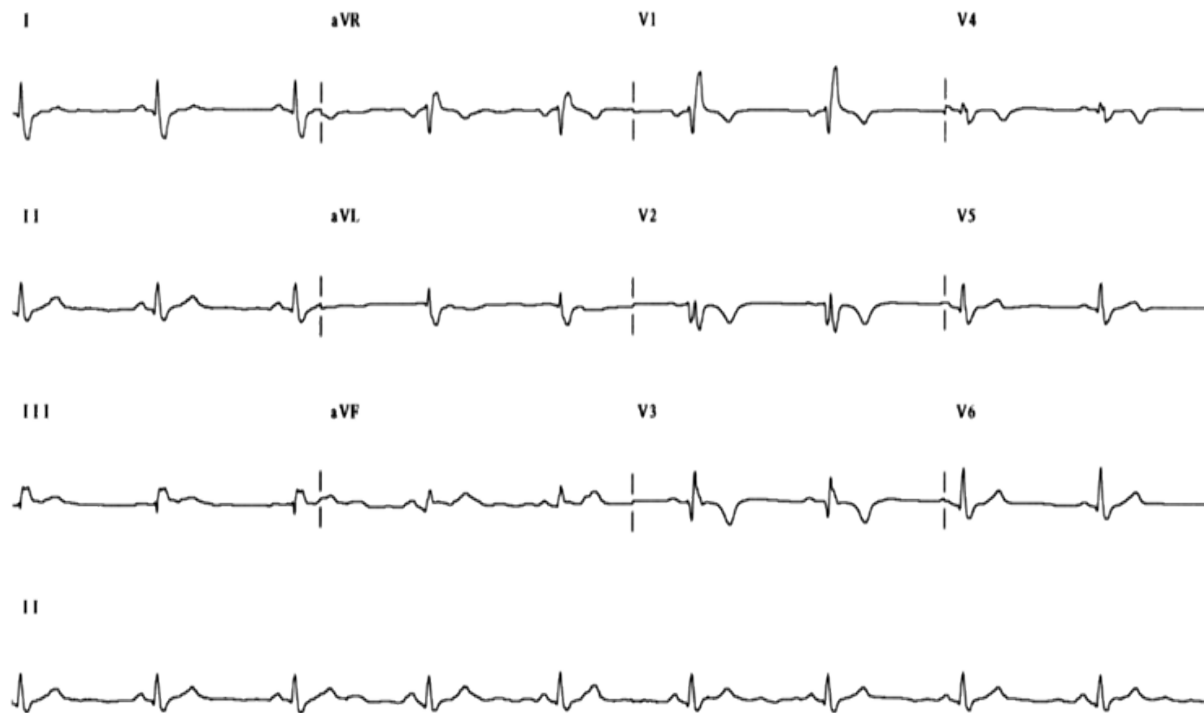
6) Question: What specific information do you want to look for on exam?

EXAM: On examination he is a middle-aged man in some distress. Vital signs: BP 110/60 supine, 105/58 sitting (equal in both arms); Pulse regular and 103 supine, 105 sitting; RR 18/minute; temperature 99°F. HEENT normal. There is questionable neck vein distention at 45° incline. Chest is clear to auscultation and percussion. Cardiac rhythm is regular with a normal S1 and S2; no audible murmurs, rubs, or gallops. Abdominal exam is normal. Extremity exam shows trace ankle edema and 1+ pulses throughout without palpable cords. His groin shows no evidence of oozing at the catheterization site with a minimal amount of ecchymosis and swelling.

7) Question: what should you do next?

8) Question: what additional information are you looking for in the chart?

Current EKG: Chest Pain



9) Question: what are possible explanations for the patient's presentation?

10) Question: What should you do now?

#### References:

1. 2011 ACCF/AHA Focused Update Incorporated Into the ACC/AHA 2007 Guidelines for the Management of Patients With Unstable Angina/Non-ST-Elevation Myocardial Infarction: A Report of the American College of Cardiology Foundation/American Heart Association Task Force on Practice Guidelines. *J Am Coll Cardiol*. 2011;57(19):e215-e367. Available at: <http://content.onlinejacc.org/article.aspx?articleid=1146460>
2. Chest Discomfort. *Harrison's Principles of Internal Medicine*. 17<sup>th</sup> edition. Thomas Lee. 2008. 87-91.
3. 2011 ACCF/AHA/SCAI Guideline for Percutaneous Coronary Intervention: A Report of the American College of Cardiology Foundation/American Heart Association Task Force on Practice Guidelines and the Society for Cardiovascular Angiography and Interventions. *J Am Coll Cardiol*. 2011;58(24):e44-e122. Available at: <http://content.onlinejacc.org/article.aspx?articleid=1147816>
4. 2013 ACCF/AHA Guideline for the Management of ST-Elevation Myocardial Infarction: A Report of the American College of Cardiology Foundation/American Heart

Association Task Force on Practice Guidelines. *J Am Coll Cardiol*. 2013;61(4):e78-e140. Available at: <http://content.onlinejacc.org/article.aspx?articleid=1486115>